

# Magnetic Resonance Imaging Spectrum of Central Nervous System Involvement in Scrub Typhus: A Case Series

Priyanka Yadav<sup>1</sup>, Uttam Yadav<sup>2</sup>

<sup>1</sup>Associate Professor, Department of Radio-diagnosis, KGMU Lucknow, Uttar Pradesh, India. <sup>2</sup>Assistant Professor, Department of Radio-diagnosis, Hind institute of medical sciences Sitapur, Uttar Pradesh, India

## Abstract

**Background:** Scrub typhus is a compelling cause of acute febrile illness in endemic regions and is usually complicated by central nervous system (CNS) involvement. Neuroimaging findings are heterogeneous and often overlap with other infectious and inflammatory conditions. **Material and Methods:** This retrospective case series included patients with serologically confirmed scrub typhus who underwent MRI for neurological manifestations. MRI findings were analysed for lesion distribution, signal characteristics, diffusion restriction, haemorrhage, and enhancement patterns. **Results:** Fifteen patients demonstrated a wide spectrum of MRI abnormalities, including encephalitis, meningoencephalitis, deep gray matter involvement, vasculitic infarcts, haemorrhage, cerebellitis, and spinal cord involvement. Several imaging patterns mimicked infective meningitis, viral encephalitis, acute disseminated encephalomyelitis (ADEM), and primary CNS vasculitis. **Conclusion:** Scrub typhus shows diverse MRI manifestations reflecting underlying inflammatory and vasculitic pathology. Familiarity with these imaging patterns can aid early diagnosis and prompt treatment in endemic regions.

**Keywords:** Scrub typhus, MRI brain, encephalitis, vasculitis, tropical infections.

Received: 25 February 2026

Revised: 15 March 2026

Accepted: 31 March 2026

Published: 06 April 2026

## INTRODUCTION

Scrub typhus is a zoonotic infection caused by *Orientia tsutsugamushi*, transmitted through the bite of infected chiggers.<sup>[1]</sup> It is endemic in the “tsutsugamushi triangle,” encompassing large parts of South and Southeast Asia.<sup>[2]</sup> Classically presenting with acute febrile illness, rash, and eschar, scrub typhus frequently involves multiple organ systems.<sup>[3]</sup> Neurological complications range from mild meningitis to severe encephalitis and stroke-like presentations.<sup>[4-6]</sup>

CNS involvement is caused by endothelial injury and small-vessel vasculitis, leading to disruption of the blood–brain barrier, inflammation, and ischemia.<sup>[4,7]</sup> Clinical manifestations are often nonspecific, and laboratory findings may overlap with those of other tropical infections, such as viral encephalitis, tuberculosis, leptospirosis, and cerebral malaria.<sup>[8,9]</sup> Neuroimaging, therefore, plays a crucial role in raising suspicion of CNS involvement in scrub typhus.<sup>[10-13]</sup> While case reports and small series have described isolated imaging findings, comprehensive characterisation of the MRI spectrum remains limited. This series aims to illustrate the range of MRI abnormalities in scrub typhus with neurological manifestations and highlight imaging patterns that may assist radiologists in suggesting the diagnosis.

## MATERIALS AND METHODS

**Study Design and Patients:** This retrospective observational case series was conducted at a tertiary care centre in North India. Patients with acute febrile illness and

neurological symptoms who were serologically positive for scrub typhus (IgM ELISA) and underwent brain MRI were included. Patients with alternative confirmed diagnoses were excluded.

**MRI Protocol:** MRI examinations were performed on 1.5T Signa GE Healthcare scanners and included axial T1-weighted, T2-weighted, FLAIR, diffusion-weighted imaging (DWI) with ADC maps, susceptibility-weighted imaging (SWI), and post-contrast T1-weighted sequences. Spine MRI was performed in cases with myelopathic symptoms.

**Image Analysis:** Images were reviewed by a radiologist with eight years of experience. Lesions were assessed for location, symmetry, signal characteristics, diffusion restriction, haemorrhage, and enhancement pattern. Imaging findings were correlated with clinical presentation and laboratory parameters.

**Ethical Considerations:** Institutional ethics committee approval was waived due to the case series's retrospective nature. Patients' confidentiality was well maintained.

**Address for correspondence:** Dr. Priyanka Yadav, Associate Professor, Department of Radio-diagnosis, KGMU Lucknow, Uttar Pradesh, India  
E-mail: [priyankasih1990@gmail.com](mailto:priyankasih1990@gmail.com)

**DOI:**  
10.21276/amit.2026.v13.i1.570

**How to cite this article:** Yadav P, Yadav U. Magnetic Resonance Imaging Spectrum of Central Nervous System Involvement in Scrub Typhus: A Case Series. *Acta Med Int.* 2026;13(1):921-924.

**RESULTS**

**Clinical Features:** Patients in our case series were presented with fever, headache, altered sensorium, seizures, focal neurological deficits, or ataxia. Eschar was identified in a minority of cases. Cerebrospinal fluid analysis showed lymphocytic pleocytosis with mildly elevated protein. All included patients were IgM ELISA-positive for scrub typhus.

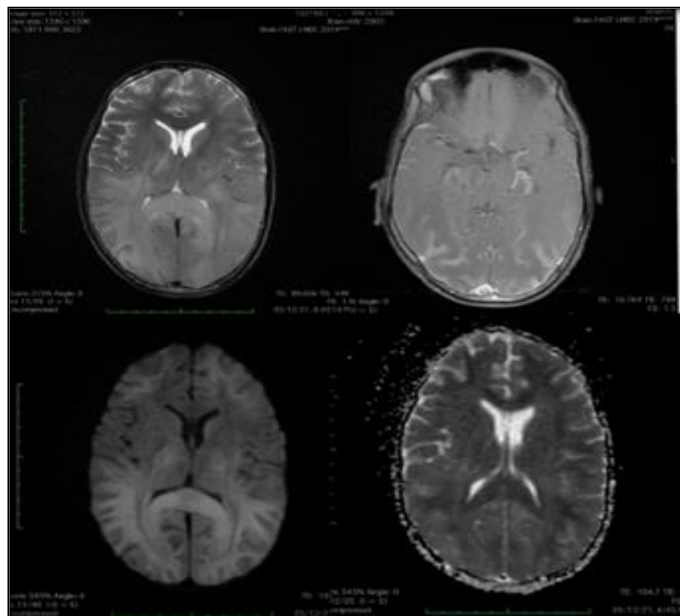
**MRI Findings**

**The MRI spectrum included:**

- Meningoencephalitis: Cortical and subcortical T2/FLAIR hyper-intensities with leptomeningeal enhancement.
- Deep grey matter involvement: Bilateral thalamic and basal ganglia T2/FLAIR hyper-intensities were noted with or without diffusion restriction.
- White matter lesions: Patchy or confluent periventricular and subcortical hyper-intensities were seen.
- Ischemic changes: Acute infarcts in vascular watershed distributions or non-territorial areas were seen in a few cases, suggesting vasculitic infarcts.
- Hemorrhagic lesions: Patchy areas of hemorrhagic lesions were seen on SWI.
- Cerebellar involvement: T2/FLAIR hyper-intensities were seen involving the cerebellum with or without enhancement.
- Spinal cord involvement: T2 hyper-intensity consistent with myelitis was seen in a few cases.

**Radiological Differential Diagnosis:** Imaging differentials include viral encephalitis, tubercular meningitis, ADEM, primary CNS vasculitis, and metabolic encephalopathies.<sup>[4,12,14]</sup> Bilateral thalamic involvement, multifocal infarcts, and hemorrhagic foci in a patient with an

acute febrile illness should raise suspicion for scrub typhus in areas where the disease is common.<sup>[2,10]</sup>



**Figure 1: Magnetic resonance imaging performed on a 1.5 T scanner (Signa; GE Healthcare). (a) Axial T2-weighted image showing white matter lesions in the bilateral parieto-occipital region, splenium of the corpus callosum. (b) Postcontrast T1-weighted image shows leptomeningeal enhancement in the bilateral parietooccipital region. (c) Diffusion-weighted image reveals hyper-intensity in the bilateral parieto-occipital region and the splenium of the corpus callosum. (d) The corresponding apparent diffusion coefficient image reveals diffusion restriction in the bilateral parieto-occipital region and splenium of the corpus callosum.**

**Table 1: Spectrum of magnetic resonance imaging findings in central nervous system scrub typhus (n = 15)**

Case	Age/sex	Neurological presentation	MRI brain/spine findings	Radiological diagnosis
1	42/M	Fever with rash and headache	Cortical-subcortical FLAIR hyper-intensities with leptomeningeal enhancement	Meningoencephalitis
2	22/M	Headache	leptomeningeal enhancement	Meningitis
3	14/M	Focal neurological deficit	T2/FLAIR hyper-intensities in right centrum semiovale, pons, bilateral middle cerebellar peduncle and C2-C3 spinal cord	Encephalitis with myelitis
4	40/F	Fever, altered sensorium, Ataxia	Cerebellar hemispheric T2/FLAIR hyper-intensity with associated edema in cerebellum, bilateral parietotemporal and occipital lobe. Petechial haemorrhage in right frontal lobe	Cerebellitis, vasculitis haemorrhage and encephalitis
5	60/M	Focal weakness	Acute infarcts involving corona radiata, bilateral frontal and left parietal region	Vasculitic infarcts
6	45/M	Fever with Headache	Diffuse leptomeningeal enhancement without parenchymal involvement	Meningitis
7	33/M	Confusion	Patchy periventricular and subcortical white matter FLAIR hyper-intensities	ADEM-like pattern
8	52/M	Altered sensorium	Restricted diffusion involving periaqueductal white matter of mid brain and ventral pons	Rhombencephalitis
9	24/M	Seizures	Temporal lobe cortical FLAIR hyper-intensity without haemorrhage	Viral encephalitis-like pattern
10	12/M	Focal weakness	Hemorrhagic infarct with blooming on susceptibility-weighted imaging	Vasculitic haemorrhage
11	39/F	Fever, altered sensorium	Cortical-subcortical FLAIR hyper-intensities with leptomeningeal enhancement with blooming of right basal ganglia	Meningoencephalitis with basal ganglia haemorrhage
12	75/M	Altered sensorium	Diffuse cerebral edema with sulcal effacement with involvement of basal ganglia, PLIC, thalamus, pons	Encephalopathy with meningoencephalitis

13	27/F	Headache	Diffuse cerebral edema with sulcal effacement with involvement of deep and periventricular white matter	Encephalopathy
14	36/M	Sensory symptoms	Patchy thoracic spinal cord T2 hyper-intensity	Partial myelitis
15	42/F	Confusion	Multifocal cortical and subcortical FLAIR hyper-intensities	Encephalitis

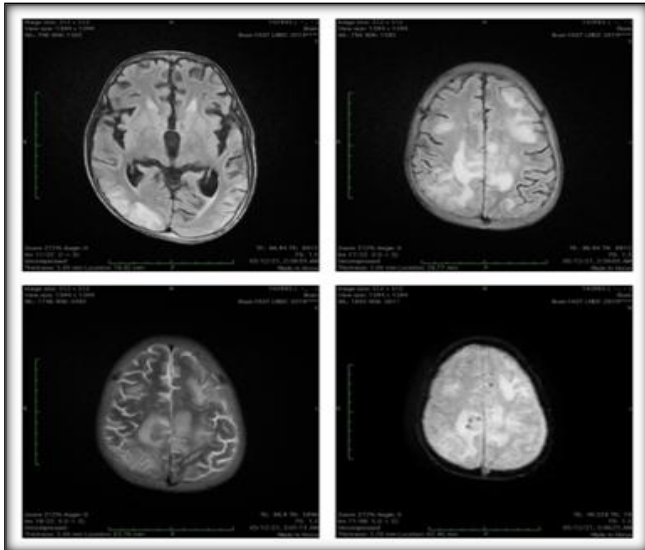


Figure 2: Magnetic resonance imaging performed on a 1.5 T scanner (Signa; GE Healthcare). (a) (b) Axial FLAIR -weighted image showing bilateral asymmetrical hyper-intense white matter lesions in the bilateral fronto-parieto-occipital region. (c) Axial T2 -weighted image showing bilateral asymmetrical hyper-intense white matter lesions in the bilateral fronto-parieto-occipital region. (d) SWI images show hypo-intense lesions involving bilateral frontal and parietal regions, s/o haemorrhages.

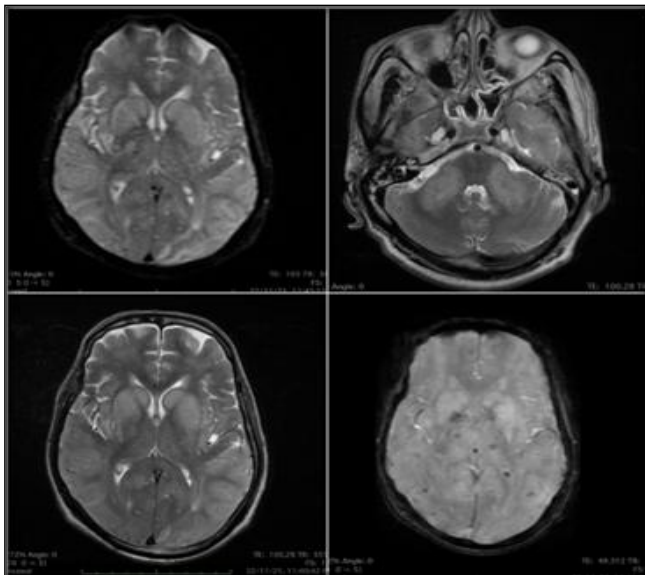


Figure 3: Magnetic resonance imaging performed on a 1.5 T scanner (Signa; GE Healthcare). (a) (b) Axial FLAIR -weighted image showing bilateral asymmetrical hyper-intense white matter lesions in the bilateral fronto-parieto-occipital region. (c) Axial T2 -weighted image showing bilateral asymmetrical hyper-intense white matter lesions in the bilateral fronto-parieto-occipital region. (d) SWI images show hypo-intense lesions involving bilateral frontal and parietal regions, s/o haemorrhages.

## DISCUSSION

Scrub typhus demonstrates a broad spectrum of CNS involvement. Meningeal involvement is reported more frequently in *Orientia tsutsugamushi* infection compared with other rickettsial diseases.<sup>[15]</sup> The overall radiological picture of the CNS is consistent with meningoencephalitis, as seen in our case series.<sup>[15]</sup> *Rickettsia* invades and multiplies within the vascular endothelium, leading to widespread vasculitis involving capillaries, arterioles, and small arteries.<sup>[16]</sup> Vasculitic changes manifested as multifocal infarcts and hemorrhagic lesions, which may mimic primary CNS vasculitis or embolic stroke.<sup>[6,13]</sup>

Deep gray matter involvement, particularly of the thalami and basal ganglia, reflects *O. tsutsugamushi*'s predilection for endothelial cells and small vessels.<sup>[4,7]</sup> White matter abnormalities resembling ADEM were also observed.<sup>[12]</sup> Posterior fossa involvement manifesting as cerebellitis and spinal cord lesions in the form of acute or partial myelitis further highlights the multisystem inflammatory nature of the disease.<sup>[11,12]</sup>

Neyaz et al. systematically summarised the neuroradiological spectrum of scrub typhus encephalitis by compiling imaging observations from the literature and presenting a case report.<sup>[17]</sup> The findings described in this case report were hyper-intensities in the bilateral subcortical white matter on T2 weighted/FLAIR images with diffusion restriction. None of the lesions showed post-contrast enhancement. Focal area of cortical T2 weighted/FLAIR hyper-intensity in the right frontal opercular region with foci of micro haemorrhage on SWI.

In a study conducted by Mishra et al., they found meningoencephalitis was the most common finding seen on MRI, which was also seen in our case series.<sup>[18]</sup>

A study by Sood et al. shows microhemorrhages in the corpus callosum and subcortical white matter in the bilateral centrum semiovale on SWI images, without mass effect or perilesional edema. Pachymeningeal enhancement along bilateral frontotemporoparietal lobes on postcontrast T1-weighted gradient sequence.<sup>[19]</sup> These imaging findings were also consistently seen in a few of our cases.

Another study by Yum et al. demonstrated neuroimaging involvement of the brainstem, left cerebellar peduncle, and left basal ganglia. Contrast-enhanced MRI revealed multiple nodular parenchymal enhancements along with leptomeningeal enhancement involving the brainstem, left temporal periventricular region, and right cerebellar peduncle.<sup>[20]</sup>

In a case report by Kim et al., imaging findings included high signal intensity in the right parietooccipital cortex and the right corona radiata on FLAIR images, with true diffusion restriction.<sup>[21]</sup>

Thus, as stated in other case series, our cases also showed meningoencephalitis, deep gray matter involvement, white matter lesions, hemorrhagic lesions, and cerebellar and spinal cord involvement as common radiological findings in scrub typhus encephalitis.

## CONCLUSION

Early recognition is crucial, as scrub typhus is treatable with doxycycline, and delayed therapy may result in significant morbidity or mortality. As no imaging feature is specific, clinicroadiological correlation is essential. Early recognition of these patterns, especially in endemic regions, enables timely treatment and improved outcomes, while MRI remains key in diagnosis and exclusion of mimics.

## Financial support and sponsorship

Nil.

## Conflicts of interest

There are no conflicts of interest.

## REFERENCES

- Mahajan SK. Scrub typhus. *J Assoc Physicians India*. 2005;53:954–958.
- Bhuvaneshwari V, Amsaveni R. Emerging threat of scrub typhus: A call for greater awareness and research. *Int Immunopharmacol*. 2025 Oct 30;164:115387. doi: 10.1016/j.intimp.2025.115387. Epub 2025 Aug 20. PMID: 40840137.
- Varghese GM, Janardhanan J, Trowbridge P, et al. Scrub typhus in South India: clinical and laboratory manifestations, genetic variability, and outcome. *Lancet Infect Dis*. 2015;15(10):1123–1132.
- Lee SH, Kim SY, Jung SI, et al. Neurological manifestations of scrub typhus. *J Clin Neurol*. 2007;3(2):76–81.
- Pai H, Sohn S, Seong Y, et al. Central nervous system involvement in patients with scrub typhus. *Clin Infect Dis*. 1997;24(3):436–440.
- Hsu YH, Chen HI. Acute ischemic stroke in scrub typhus: a case report and literature review. *Acta Neurol Taiwan*. 2016;25(2):63–68.
- Dhandapani S, et al. Scrub typhus encephalitis: clinical spectrum and predictors of outcome. *Neurol India*. 2017;65(6):1316–1321.
- Sharma A, et al. MRI findings in scrub typhus encephalitis: a case series. *Indian J Radiol Imaging*. 2019;29(4):415–421.
- Zhang L, et al. Reversible splenic lesion syndrome associated with scrub typhus. *BMC Neurol*. 2020;20:219.
- Basu S, et al. Imaging spectrum of CNS infections in tropical regions. *Radiographics*. 2021;41(2):403–423.
- Rajapakse S, Weeratunga P, Sivayoganathan S, Fernando SD. Clinical manifestations of scrub typhus. *Trans R Soc Trop Med Hyg*. 2012;106(7):423–432.
- Lee YJ, et al. Scrub typhus presenting with acute disseminated encephalomyelitis-like features. *AJNR Am J Neuroradiol*. 2018;39(6):E68–E70.
- Kwon HY, et al. Hemorrhagic complications in scrub typhus-associated encephalitis. *Infection*. 2020;48(5):731–739.
- Singh AK, et al. MRI spectrum of acute febrile encephalopathy in tropical infections. *Clin Radiol*. 2022;77(4):e273–e282.
- KimDM, KimYS, ChoHY, LeeYB. Scrub typhus meningoencephalitis occurring during doxycycline therapy for *Orientia tsutsugamushi*. *Diagn Microbiol Infect Dis* 2011;69:271–4. Available from: <http://www.ncbi.nlm.nih.gov/pubmed/21353950>.
- Boorugu H, Chrispal A, Gopinath KG, Chandy S, Prakash JJ, Abraham AM, et al. Central nervous system involvement in scrub typhus. *Trop Doct* 2014;44:36–7.
- Neyaz Z, Bhattacharya V, Muzaffar N, Gurjar M. Brain MRI findings in a patient with scrub typhus infection. *Neurol India* 2016;64:788. Available from: <http://www.neurologyindia.com/text.asp?2016/64/4/788/185397>.
- Misra UK, Kalita J, Mani VE. Neurological manifestations of scrub typhus. *J Neurol Neurosurg Psychiatry* 2015;86:761–6.
- Sood S, Sharma S, Khanna S. Role of advanced MRI brain sequences in diagnosing neurological complications of scrub typhus. *J Clin Imaging Sci* 2015;5:11.
- Yum KS, Na SJ, Lee KO, Ko JH. Scrub typhus meningoencephalitis with focal neurologic signs and associated brain MRI abnormal findings: Literature review. *Clin Neurol Neurosurg* 2011;113:250–3.
- Kim JH, Lee SA, Ahn TB, Yoon SS, Park KC, Chang DI, et al. Polyneuropathy and cerebral infarction complicating scrub typhus. *J Clin Neurol*. 2008;4:36–9.