

Healicol: An Alternate to Flap Cover for Bare Bones and Tendons

Prema Dhanraj¹, Naveen N², Ramesh Babu K³, Mahesh M. S², Hanumanthaiah K. S⁴

¹Prof & HOD, Dept of Plastic Surgery, Raja Rajeswari Medical College & Hospital, Bengaluru, Karnataka, India, ²Senior Resident, Dept of Plastic Surgery, Raja Rajeswari Medical College & Hospital, Bengaluru, Karnataka, India, ³Prof, Dept of Plastic Surgery, Raja Rajeswari Medical College & Hospital, Bengaluru, Karnataka, India, ⁴Prof, Dept of General Surgery, Raja Rajeswari Medical College & Hospital, Bengaluru, Karnataka, India

Article Information

Received: 27 Sep 2015

Accepted: 16 Nov 2015

Plagiarism software: Turnitin

Keywords:

Skin replacement, Healicol, Bare bone, Joints and tendons.



Naveen N

ABSTRACT

Background: Wounds with bare bone, joint and tendons in the extremities have been a formidable challenge to plastic surgeons. Although several skin substitutes are used in West, as both dermal and epidermal analogue, they are expensive and most of them are unavailable in India. It is in this scenario that Healicol – a type 1 pure collagen as a possible dermal substitute is being investigated. The material 'Healicol' is a type-1 native collagen derived from the bovine source and is bioengineered, biocompatible and biodegradable skin substitute. The advantages of Healicol have led us to an increase in its use for complex wounds. Medical literature on Healicol, thus far has only reported its use for superficial burns and ulcers. **Materials & Methods:** The purpose of this study was to evaluate the advantages of using an inexpensive, easily available, bioengineered skin substitute 'Healicol' for the closure of bare bone, joints and tendon. **Results:** Healicol was used in three patients with two patients having undergone surgery involving use of Healicol for bare bones, joints and tendons after release of contracture following burns and trauma, and one patient was treated with Healicol as an outpatient procedure for bare bones following electrical burns. The mean hospital stay was 15 days. In all the three cases, a clear neodermis had covered the bones and joints in 5 days time and was ready to support the take of skin graft. **Conclusions:** Based on our initial experience, Healicol skin substitute offers an excellent alternative for rapid reconstruction obviating the need for flap cover for wounds that have been difficult to reconstruct.

INTRODUCTION

Wounds of the extremity with exposed bones and tendons remain a formidable clinical challenge. The standard options for such wounds consist of local flaps, distant flaps and free flaps. With elevated complication and failure rates, using flap for cover is scrupulously hard also compounded by limited availability of choices of local tissue. Often these patients are preferred for free tissue transfer as the only reconstructive choice which is also associated with donor site morbidity, prolonged operation time and hospital stay. Immediate tissue cover is vital to prevent bone desiccation and infection. It is here that bioengineered skin substitute Healicol provides an alternative skin cover.

We present here a three patients case series, treated using an easy two staged technique with Healicol and thin split thickness skin grafting to effect healing in those difficult wounds. A pilot study consistently showed incorporation of Healicol into the wound bed and formation of a neodermis by day 4-5 post Healicol application. This neodermis was vascularised and showed good capillary bleeding (Figure 1). A split thickness graft placed on this neodermis on the 5th post Healicol day revealed a good graft take. The time from application of Healicol to incorporation of collagen into the wound bed was consistently seen between 4th and 5th day in all our cases. This is perceived as indicating adequate vascularisation and biodegradation of the bovine collagen fibres. Healicol triggers normal inflammatory response to activate neoangiogenesis in injured tissue.¹⁻³

At the time of writing, no study to the best of our knowledge had been published pertaining to use of Healicol for coverage of bare bones, joints and tendons.

Access this article online

Website:	Quick Response code
www.actamedicainternational.com	
DOI: 10.5530ami.2016.1.30	

Corresponding Author:

Dr. Naveen N, Senior Resident, Dept of Plastic Surgery, RRMCH&H, 90, 14th Main, 14th Cross, 2nd Stage, 2nd Phase, West of Chord road, Mahalakshimpuram, Bangalore – 560086. Phone: 9980023372. E-mail: naveen_uno1@yahoo.co.in

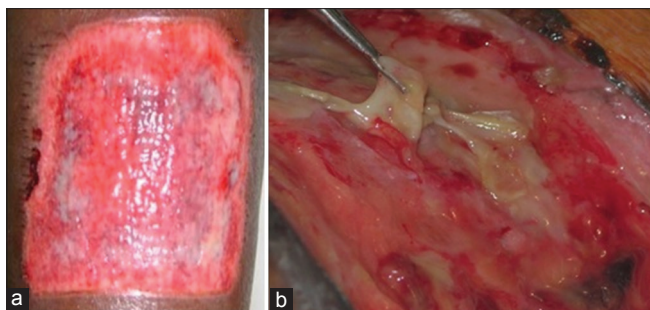


Figure 1: Healicoll incorporated into deeper structures (a); Showing capillary bleeding and incorporation of Healicoll (b)

MATERIALS AND METHODS

Study Design

This is a prospective case study using Healicoll skin substitute for exposed bones, joints and tendons.

Materials

Healicoll is a type-1 pure collagen membrane derived from bovine source and maintains a moist environment at the wound surface and is biocompatible, biologically active, biodegradable and bioengineered skin substitute with absence of antigenicity, low cost, long shelf life and minimum storage requirements. It accelerates the healing process and improves the quality of the wound. It gets totally absorbed and there are no itching, irritation, impairment to movement or requires special dressing care. Hospitalization cost is significantly reduced. It is stored at room temperature with a shelf life of 3 years. The material used is manufactured by Advanced Biotech Products Pvt. Ltd., India.⁴

Methods

Application procedure - Healicoll collagen comes in a sterile pack; the collagen sheet (it comes in a wide variety of sizes-from 5x5 cm to 20x25 cm. The sheet that suits the ulcer size is used) is covered by a transparent film on one side and by an opaque plastic backing sheet on the other. The pack is soaked in sterile saline for 5 min and then the transparent sheet is peeled off. It is then applied over the area to be covered along with the backing sheet for easy handling. The opaque plastic sheet is peeled off, leaving the collagen in situ. After placing the collagen sheet over the desired area, air bubbles trapped beneath are carefully removed. The wound is dressed with antibiotic impregnated gauze, pads and bandaged.

Dressings – Wound was inspected on 5th post Healicoll application. Healicoll had undergone degradation, the shiny Healicoll was completely absent and in its place a neodermis was present.

Patients – Three patients (1 male and 2 female) were in the study. One male patient aged 36 years was admitted with

electrical burns of the upper extremities with exposed bones of the right carpometacarpal and proximal interphalangeal joint. Healicoll was applied over the joint as an out-patient procedure. The wound healed in 10 days time.

A 12 year old child was admitted with severe post traumatic deformity of the foot and another child aged 8 years was admitted with severe burn scar contracture of the hand. These two patients were taken up for surgery to release the contracture of the foot and hand. During the release bones, joints and tendon were exposed. Healicoll was applied and secured in place with staples and dressed with paraffin gauze and bandage. The first dressing change was performed on 5th post operative day. Healicoll had formed a neodermis to support the take of skin graft. Patient was taken up for surgery and a split thickness skin graft was used to cover this neodermis.

RESULTS

In all three patients, Healicoll was applied directly over the bare bones, joints, and tendon with excellent results. The time from Healicoll application to subsequent auto grafting was 5 days. There was good take of the skin graft with no complication. There was significant reduction in pain at the operated site. All the three patients were discharged by 10-15 days post operative period.

Case 1

A 36 year old man sustained electrical burns of upper extremities. Wound debridement resulted in exposure of the metacarpal bone of the thumb and proximal phalanx of index finger. The exposed bones were treated with Healicoll and dressed with paraffin gauze and bandaged (Figure 2). On 5th post Healicoll application wound had healed and did not require further treatment (Figure 3).

Case 2

A 12 year old female presented with severe post traumatic deformity of the right foot. Patient was taken for surgery to release contracture of the right foot. The resulting wound consisted of exposed metatarsal bones of 2nd - 4th toes. The open areas were covered with Healicoll skin substitute (Figure 4). First dressing change was on 5th post operative day which revealed a clear neodermis covering the bare bone. A sheet graft was placed on this layer and wound was dressed with paraffin gauze and bandaged. The dressing was removed on post operative day 10. The graft take was good (Figure 5).

Case 3

An 8 year old female child with post burn contracture of the left hand was taken to the operation room for the release of contracture. The contracture was so severe that during

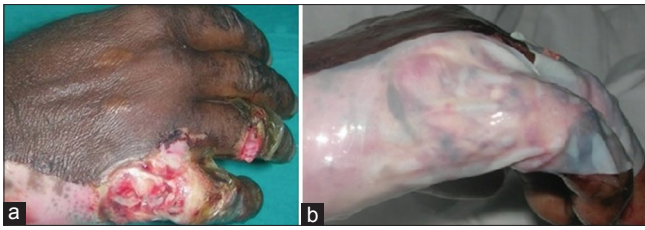

Figure 2: Exposed bare bone - Metacarpal and phalanx of little finger (a); Healicoll application with the opaque back sheet still present (b)

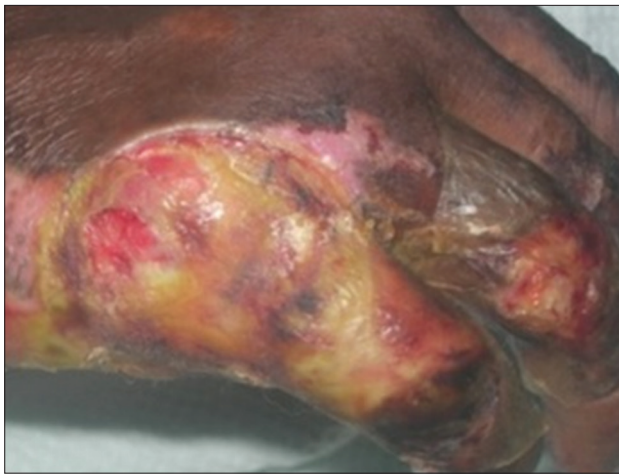

Figure 3: Five days after Healicoll application and no further treatment required

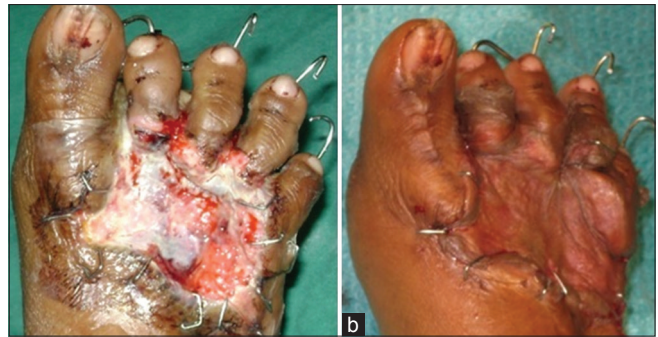


Figure 5: On 5th day a gel like substance is seen covering the bones (a); Skin graft applied on 5th day (b)

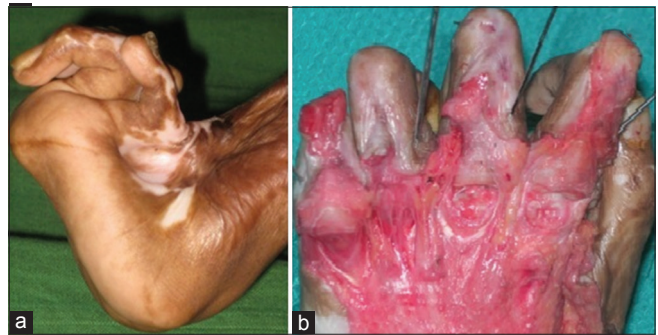

Figure 6: Post burns severe contracture of the hand (a); After contracture release bare bones and tendons are seen on dorsum of the hand (b)

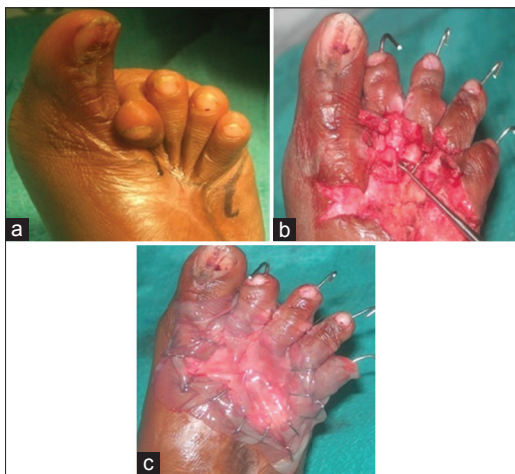

Figure 4: Severe contracture deformity (a); Post contracture release 2nd to 4th metatarsal bones sans covering (b); Healicoll applied (c)

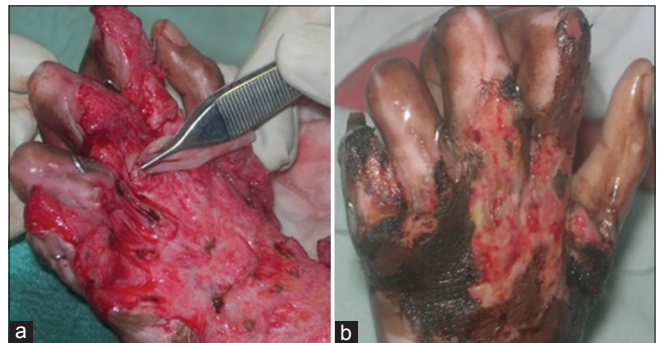


Figure 7: Packing the joint space with healicoll (a); Post operative day 7 shows 90% graft take and some areas of epidermolysis (b)

the procedure the bones and joints got exposed (Figure 6). The open joint was packed with Healicoll and sutured in place with absorbable material. The other areas of exposed bones and tendon were then covered with Healicoll. On 5th day- post of Healicoll application, a neodermis had formed to cover the exposed bones and joints. A sheet graft was placed on this neodermis and wound was dressed. Dressing change on 10th post operative day showed skin graft take to be over 90% (Figure 7). Dressing was continued for one more week for complete healing.

DISCUSSION

Reconstruction of long standing deformities of extremities requires experience and surgical judgement. In addition if there are exposed bones, joints and tendons it further adds to the problem, posing a considerable challenge. Multiple repair approaches have been described to address exposed bones and joints of the extremity. Although pedicle and free flaps offer the best one step options for coverage of defects with exposed bones and joints, it is associated with donor site morbidity, prolonged operation time and hospital stay. It is here that bioengineered skin substitute Healicoll may provide an alternative for rapid reconstruction.

Collagen dressings have been used in various forms for tissue repair and wound healing, as it constitutes more than 80% of the structural proteins of the body. Collagen dressings maintain a physiologically moist environment that promotes healing. It is an ideal material for tissue regeneration compared to other non-biological products.⁵

Healicoll is a pure Type1 collagen of bovine origin. This product was first tried out as donor dressing and was found to aid in wound healing. Healicoll also improved vascularity, contained infection and promoted granulation tissue when used on infected wounds. The Healicoll collagen gets incorporated into the wound to form a clear layer of neodermis. This neodermis provides a good matrix for cellular and vascular replacement and forms an excellent recipient bed for skin grafting. The ability to vascularize over bones and tendons is particularly useful in wounds that otherwise would have required the use of free tissue transfer. We have been using this product since January 2007 and we have got very encouraging results. The Possible mechanism of action of Healicoll is attributed to the moist wound bed cell signalling, early wound healing and neovascularisation. Till date, we have used Healicoll as a donor site dressing, over acute burn raw areas, non healing chronic wounds and post traumatic raw areas.^{6,7}

Healicoll was compared with Integra skin substitute, which is available for routine use in the West as a dermal substitute. The prohibitive cost of Integra makes it impossible as a treatment option in majority of the developing countries. More over it takes almost three weeks for silicon sheet to be separated before skin grafting.⁸ It is in this scenario, that the potential of Healicoll for dermal incorporation was tried and was found to be significant. The dermal regeneration substitute is in the lines of Integra skin substitute, which works as a collagen scaffold.^{9,10} Healicoll skin substitute also works similar to Integra. The advantage of Healicoll over Integra is that in Healicoll the native cells climb and lay down native matrix protein and collagen. The increased dermal component offers the healing wound bed more tensile strength and pliability, and hence better functional and aesthetic results. This increased pliability and better quality of graft in the post operative period explains that there is some increase in the dermal component after Healicoll application, and the graft was getting placed over some dermis instead of over fat or granulation alone. Wound covered with Healicoll compared to skin graft application alone results in decreased formation of contractures and better pliability.¹¹⁻¹⁴ The potential of this collagen dressing to reduce pain significantly is clinically relevant. The advantage of Healicoll is that it is available at a very affordable price, ready to support a skin graft in 5 days time and reduces hospitalization and cost.

CONCLUSION

As seen in this study, Healicoll can be used successfully for reconstruction of complex wounds obviating the need for flap cover. Though the study pool was small, it creates positive ground for a larger study to evaluate whether the same results can be emulated. This approach was found to have nominal patient morbidity and hospital stay in our study and has demonstrated to be successful in healing of complex wounds.

REFERENCES

1. Gunasekaran Subramanian, Marilyn Kwolek, Dhanikachalam A, Narayan RP: A comparative second degree burn treatment trial collagen dressing vs, silver sulphadiazine alone. American Society for Dermatologic surgery, 2005.
2. Rajendran MK, Swaminathan T, Sivakumar M, Gunasekaran S. Improved healing of lower extremity ulcer using advanced collagen membrane. Presented at The Southern California Tissue Engineering Symposium Sep 27th 2002, at University of California, Los Angeles.
3. Gunasekaran Subramanian, Marilyn Kwolek, Dhanikachalam A, Narayan RP: A comparative second degree burn treatment trail collagen dressing VS silver sulphadiazine alone. 31st Annual meeting of the society for Biomaterial, 2006, Pittsburgh, Pennsylvania USA.
4. abpdermal.com. Chennai, Advanced Biotech Products (P) LTD; ©2013. Available from: <http://www.abpdermal.com/healicoll.html>.
5. Gunasekaran Subramanian, Marilyn Kwolek, Dhanikachalam A, Kilaru PG. Clinical review of a new bioengineered collagen dressing on diabetic ulcer wound. Society for biomaterial, 2007.
6. Giovannini UM, Teot L. Aesthetic complex reconstruction of the lower leg: Application of a dermal substitute (Integra) to an adipofascial flap. *Br J Plast Surg*, 2002; 55: 171.
7. Mustoe Thomas A, O'Shaughnessy, Kristina, Kloeters, Oliver. Chronic wound pathogenesis and current treatment strategies: A unifying hypothesis. *Plastic and Reconst Surg: Current concepts in wound healing*, 2006; 117(78): 355-418.
8. Mac G. Jeschke, Christoph Rose, Peter Angele, Bernd Fuchtmeier, Michael N, Nelich and Ulrich Bolder. Development of new reconstructive techniques: Use of Integra in combination with fibrin glue and negative pressure therapy for reconstruction of acute and chronic wounds. *Plast Reconstr Surg*, 2004; 113(2): 525-530.
9. Chou TD, Chen SL, Lee TW, Chen SG, Cheng TY, et al. Reconstruction of burns of the upper extremities with artificial skin. *Plast Reconstr Surg*, 2001; 108: 378-385.
10. Moiemien, NS, Staiano JJ, Ojeh NO, et al. Reconstructive surgery with a dermal regeneration template: clinical and histologic study. *Plast Reconstr Surg*, 2001; 108: 93.
11. Hunt JA, Moisisidis E, Haertsch P. Initial experience of Integra in the treatment of post-burn anterior cervical neck contracture. *Br J Plast Surg*, 2005; 3: 652-658.
12. Cahn ESY, Lam PK, Liew CT, Lay HCH, Yen RSC, King WWK. A new technique to resurface wounds with composite biocompatible epidermal graft and artificial skin 2001; 50: 358.
13. Loss M, Welder V, Kunzi Meuli, Simmen C, Meyer VE. Artificial skin, split thickness autograft and cultured autologous keratinocytes combined to treat severe burn injury of 93% of TBSA. *J Burns*, 2000; 26: 644.

14. Ewa Komorowska Timek, Allen Gabriel, Della C Bennet, Duncan Miles, Subhas Gupta, et al. Artificial dermis as an alternative for coverage of complex scalp defects following excision of malignant tumors. *Plast Reconstr Surg*, 2005; 115(4): 1010.

How to cite this article: Dhanraj P, Naveen N, Babu RK³, Mahesh MS, Hanumanthaiah KS, Healicoll: An alternate to flap cover for bare bones and tendons. *Acta Medica International*. 2016;3(1):146-150.

Source of Supportwww: Nil, **Conflict of Interest:** None declared.