

Efficacy of Ultrasound-Guided versus Landmark Technique in Central Venous Catheterisation: A Prospective Comparative Study

Beyagudam Saragini Priya¹, Kalyan Chakravarthy Peddinti²

¹Final Year Post Graduate, Department of Anaesthesiology, Kamineni Institute of Medical Sciences, Narketpally, Telangana, India

²Professor and Head, Department of Anaesthesiology, Kamineni Institute of Medical Sciences, Narketpally, Telangana, India

Abstract

Background: Central venous catheterisation is an essential procedure in anaesthesia, emergency care, and intensive care practice, but landmark-guided insertion is associated with failed attempts and mechanical complications. Ultrasound guidance allows real-time visualisation of vascular anatomy and needle trajectory, improving procedural precision. The objective is to compare ultrasound-guided and landmark techniques for central venous catheterisation with respect to first-attempt success, overall success, number of attempts, catheterisation time, need for change of site, and procedure-related complications. **Material and Methods:** This prospective comparative study included 60 patients requiring central venous catheterisation at Kamineni Institute of Medical Sciences, Narketpally, Telangana, India, from December 2024 to November 2025. Patients were divided equally into Group U, who underwent ultrasound-guided catheterisation, and Group L, who underwent landmark-guided catheterisation. Baseline characteristics, indication, insertion site, procedural outcomes, and complications were recorded and compared between the two groups. **Results:** Baseline demographic and clinical variables were comparable. First-attempt success was higher in Group U than Group L. The mean number of attempts and mean catheterisation time were lower with ultrasound guidance. Overall success was 100.0% in Group U and 90.0% in Group L. Any complication occurred in 3.3% of patients in Group U and 26.7% in Group L. **Conclusion:** Ultrasound-guided central venous catheterisation demonstrated superior procedural efficacy and safety compared with the landmark technique. Its use was associated with higher first-pass success, fewer attempts, shorter procedure time, and fewer mechanical complications.

Keywords: Central venous catheterisation; ultrasound guidance; landmark technique; first-attempt success; mechanical complications; intensive care; anaesthesia.

Received: 30 March 2026

Revised: 25 April 2026

Accepted: 05 May 2026

Published: 11 May 2026

INTRODUCTION

Central venous catheterisation is a commonly performed invasive procedure in anaesthesia, critical care, emergency medicine, nephrology, and perioperative practice. It permits administration of vasopressors, hyperosmolar solutions, parenteral nutrition, blood products, and long-term intravenous therapy.^[1,2] It is also used for central venous pressure monitoring, difficult peripheral venous access, haemodialysis access, and management of haemodynamically unstable patients. Despite its broad clinical value, the procedure carries risks related to vascular puncture, pleural injury, haematoma, malposition, infection, and thrombosis. Safe insertion therefore requires careful patient assessment, aseptic technique, appropriate site selection, and technical competence.^[3,4]

The traditional landmark technique relies on surface anatomy and expected relationships between the vein and adjacent arterial or bony structures. This approach is familiar, inexpensive, and widely practised in many institutions. However, anatomical variation, obesity, hypovolaemia, previous catheterisation, short neck, coagulopathy, limited neck mobility, and emergency circumstances can reduce the reliability of external landmarks.^[5] Repeated needle passes increase patient discomfort and the probability of arterial puncture, haematoma, pneumothorax, haemothorax, and

catheter malposition. Classical reviews of central venous access complications have emphasised that unsuccessful or multiple attempts are important contributors to mechanical adverse events.^[6,7]

Ultrasound guidance offers a direct method of identifying the target vein, assessing patency, recognising anatomical variation, differentiating vein from artery, and selecting a safe puncture path. Dynamic real-time ultrasound permits visualisation of the needle during cannulation, while pre-procedural scanning can identify vessel depth, diameter, compressibility, thrombus, and overlap with the carotid artery or other nearby structures. Evidence from structured reviews, meta-analyses, and clinical studies supports ultrasound guidance as a strategy that improves first-attempt success, reduces the number of attempts, shortens access time, and lowers mechanical complication rates,

Address for correspondence: Dr. Beyagudam Saragini Priya, Final Year Post Graduate, Department of Anaesthesiology, Kamineni Institute of Medical Sciences, Narketpally, Telangana, India. E-mail: bsaraginpriya@gmail.com

DOI:
10.21276/amit.2026.v13.i2.650

How to cite this article: Priya BS, Peddinti KC. Efficacy of Ultrasound-Guided versus Landmark Technique in Central Venous Catheterisation: A Prospective Comparative Study. *Acta Med Int.* 2026;13(2):85-89.

particularly for internal jugular venous catheterization.^[5] International recommendations increasingly support ultrasound use for central venous access, especially where equipment and trained operators are available. In many Indian tertiary care settings, both techniques continue to be used depending on clinical urgency, equipment availability, and operator experience. Local prospective data remain useful because patient profile, operator training, case mix, and institutional practice patterns influence procedural performance. The present study was conducted to compare ultrasound-guided and landmark techniques for central venous catheterisation in patients requiring central venous access. The primary objective was to compare first-attempt success between the two techniques. Secondary objectives were to compare overall success, number of attempts, catheterisation time, need for change of site, and procedure-related complications.

MATERIALS AND METHODS

Study design and setting: This prospective comparative study was conducted in the Department of Anaesthesiology, Kamineni Institute of Medical Sciences, Narketpally, Telangana, India. The study period extended from December 2024 to November 2025. The study evaluated adult patients requiring central venous catheterisation in the operating room, emergency care area, or intensive care setting. The study was conducted in accordance with the principles of the Declaration of Helsinki and institutional ethical requirements. Written informed consent was obtained from eligible participants or legally acceptable representatives when clinically appropriate. Patient confidentiality was maintained throughout data handling.

Study population: A total of 60 patients requiring central venous catheterisation were included. Patients were divided into two equal groups of 30 patients each. Group U underwent ultrasound-guided central venous catheterisation, and Group L underwent catheterisation using the conventional landmark technique. Patients requiring central venous access for haemodynamic monitoring, vasopressor administration, or major surgery/anaesthesia-related indications were eligible. Patients with local infection at the proposed puncture site, uncorrected severe coagulopathy, distorted local anatomy, previous major neck or thoracic surgery affecting the planned site, refusal of consent, or incomplete procedural records were excluded.

Grouping and procedure: In Group U, a high-frequency linear ultrasound probe was used under sterile precautions to identify the vein, confirm compressibility, distinguish it from the artery, and guide needle entry. Real-time ultrasound

guidance was used whenever feasible until venous puncture was achieved. In Group L, catheterisation was performed according to standard anatomical landmarks for the selected site. Internal jugular, subclavian, and femoral routes were used according to clinical indication, operator decision, and patient suitability. In both groups, the Seldinger technique was used after venous puncture. Catheter placement was confirmed clinically and by institutional practice, including aspiration of venous blood, free flushing, pressure waveform assessment where applicable, and post-procedure imaging when indicated.

Outcome measures: Baseline variables included age, sex, body mass index, American Society of Anesthesiologists physical status, diabetes mellitus, hypertension, indication for catheterisation, and insertion site. Procedural outcomes included first-attempt success, second-attempt success, more than two attempts, overall success, mean number of attempts, catheterisation time, and need for change of site. Catheterisation time was recorded from skin preparation/needle puncture initiation to successful guidewire or catheter placement according to the procedural record. Complications assessed included arterial puncture, local haematoma, pneumothorax, catheter malposition, and occurrence of any mechanical complication.

Statistical analysis: Data were entered into a spreadsheet and analysed using standard statistical methods. Continuous variables were expressed as mean with standard deviation, and categorical variables were expressed as frequency and percentage. Intergroup comparison of continuous variables was performed using the independent samples t-test when data were normally distributed. Categorical variables were compared using the chi-square test or Fisher's exact test, as appropriate. A p-value less than 0.05 was considered statistically significant.

RESULTS

A total of 60 patients requiring central venous catheterisation were included in the study. Patients were divided into two equal groups: Group U underwent ultrasound-guided central venous catheterisation, and Group L underwent catheterisation using the landmark technique. Each group included 30 patients. All patients completed the study and were included in the final analysis.

The baseline demographic and clinical characteristics were comparable between the two groups. The mean age was 47.8 ± 14.2 years in Group U and 49.1 ± 13.8 years in Group L. Male patients constituted 60.0% in Group U and 56.7% in Group L. There was no statistically significant difference between the groups with respect to age, sex distribution, body mass index, American Society of Anesthesiologists physical status, diabetes mellitus, or hypertension [Table 1].

Table 1: Baseline demographic characteristics of the study population

Variable	Group U: Ultrasound-guided technique (n=30)	Group L: Landmark technique (n=30)	p-value
Age, years	47.8 ± 14.2	49.1 ± 13.8	0.720
Male/Female	18/12	17/13	0.795
Body mass index, kg/m ²	24.6 ± 3.2	25.1 ± 3.4	0.559
ASA I/II/III	6/15/9	5/16/9	0.932
Diabetes mellitus	7 (23.3%)	8 (26.7%)	0.766
Hypertension	9 (30.0%)	10 (33.3%)	0.781

The indications for catheterisation were also comparable between the two groups. Hemodynamic monitoring was the most common indication in both groups, followed by vasopressor administration and major surgery or anaesthesia requirement. Internal jugular venous access was the most

frequently used site in both groups. No statistically significant difference was observed between the groups with respect to indication for catheterisation or catheter insertion site [Table 2].

Table 2: Indication and site of central venous catheterisation

Variable	Group U: Ultrasound-guided technique (n=30)	Group L: Landmark technique (n=30)	p-value
Indication for catheterisation			0.917
Hemodynamic monitoring	12 (40.0%)	11 (36.7%)	
Vasopressor administration	10 (33.3%)	11 (36.7%)	
Major surgery/anaesthesia requirement	8 (26.7%)	8 (26.7%)	
Site of catheterisation			0.873
Internal jugular vein	22 (73.3%)	21 (70.0%)	
Subclavian vein	5 (16.7%)	6 (20.0%)	
Femoral vein	3 (10.0%)	3 (10.0%)	

Procedural outcomes showed better performance in the ultrasound-guided group. First-attempt success was significantly higher in Group U compared with Group L. The mean number of attempts and mean catheterisation time were significantly lower in Group U. Overall catheterisation

success was higher in the ultrasound-guided group, although the difference did not reach statistical significance. The requirement for change of site was observed only in the landmark group [Table 3].

Table 3: Comparison of procedural outcomes between the two groups

Procedural outcome	Group U: Ultrasound-guided technique (n=30)	Group L: Landmark technique (n=30)	p-value
First-attempt success	26 (86.7%)	17 (56.7%)	0.010
Second-attempt success	4 (13.3%)	8 (26.7%)	0.197
More than two attempts	0 (0.0%)	5 (16.7%)	0.052
Overall success rate	30 (100.0%)	27 (90.0%)	0.237
Mean number of attempts	1.17 ± 0.38	1.73 ± 0.83	0.002
Catheterisation time, minutes	5.2 ± 2.1	9.8 ± 4.5	<0.001
Need for change of site	0 (0.0%)	3 (10.0%)	0.237

Table 4: Comparison of procedure-related complications

Complication	Group U: Ultrasound-guided technique (n=30)	Group L: Landmark technique (n=30)	p-value
Arterial puncture	0 (0.0%)	4 (13.3%)	0.112
Local haematoma	1 (3.3%)	4 (13.3%)	0.353
Pneumothorax	0 (0.0%)	1 (3.3%)	1.000
Catheter malposition	0 (0.0%)	3 (10.0%)	0.237
Any complication	1 (3.3%)	8 (26.7%)	0.026

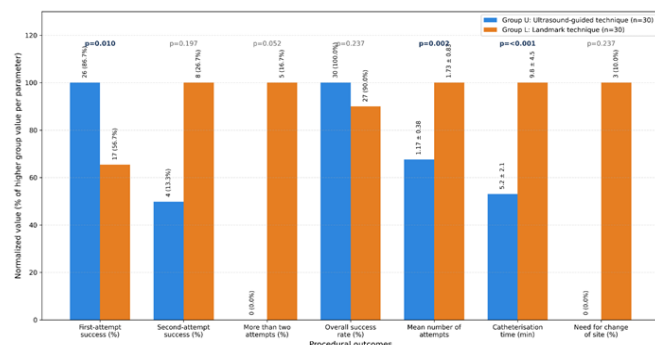


Figure 1: Comparison of Procedural Outcomes Between Ultrasound-Guided and Landmark Techniques

Mechanical complications were less frequent in Group U than in Group L. Arterial puncture, local haematoma, pneumothorax, and catheter malposition were observed more often in the landmark group. The proportion of patients developing at least one complication was significantly lower

in the ultrasound-guided group than in the landmark group [Table 4].

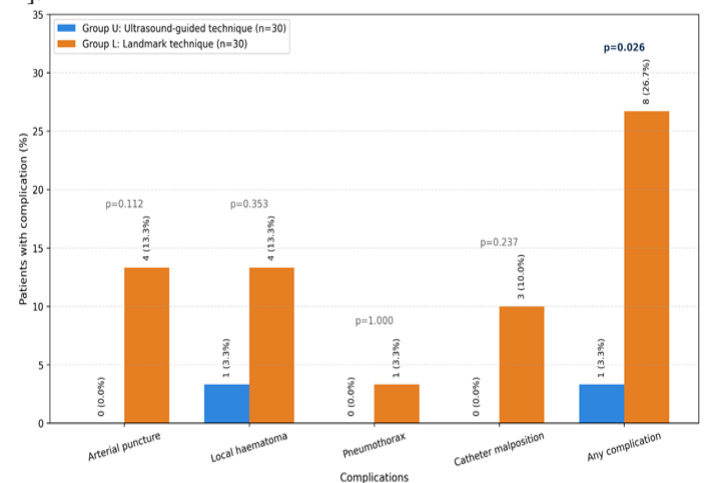


Figure 2: Comparison of Procedure-Related Complications

Overall, ultrasound-guided central venous catheterisation was associated with a higher first-pass success rate, fewer needle puncture attempts, shorter catheterisation time, and a lower complication rate when compared with the landmark technique.

DISCUSSION

The present prospective comparative study demonstrated that ultrasound-guided central venous catheterisation provided better procedural efficacy than the landmark technique. The most important finding was the significantly higher first-attempt success in the ultrasound group. First-pass access is clinically meaningful because each additional puncture increases procedure duration, patient discomfort, tissue trauma, and the probability of complications. The ability of ultrasound to visualise the target vein, identify arterial overlap, and guide needle advancement explains the improved performance observed in this study.^[2,3]

The mean number of attempts was significantly lower in the ultrasound-guided group. This finding is consistent with evidence from systematic reviews and meta-analyses showing that two-dimensional ultrasound improves success and reduces puncture attempts compared with anatomical landmarks for internal jugular venous access.^[4,5] The present study also showed a shorter mean catheterisation time with ultrasound guidance. Although ultrasound requires probe preparation and sterile covering, the gain achieved through direct vessel identification and reduced repeated needle redirection appears to outweigh this preparatory step. Similar reductions in access time have been reported in critical care and perioperative studies.^[8-12]

Overall success was 100.0% in the ultrasound group and 90.0% in the landmark group. The difference was not statistically significant, probably because of the modest sample size and the opportunity for repeated attempts or change of site in the landmark arm. However, the clinical direction favoured ultrasound guidance. In daily practice, avoiding failed catheterisation has value beyond statistical significance, especially in unstable patients requiring rapid vasopressor therapy, invasive monitoring, or major surgical support. Evidence from emergency and intensive care settings has similarly shown that ultrasound guidance improves procedural reliability across varying operator experience and patient anatomy.^[8-10,13,14]

Complications were lower in the ultrasound-guided group. Arterial puncture, haematoma, pneumothorax, and catheter malposition occurred more frequently with landmark-guided access. The overall complication rate showed a statistically significant reduction with ultrasound guidance. These findings agree with earlier reports that mechanical complications are closely related to blind needle passage, anatomical variation, and repeated attempts.^[6,7] Ultrasound can identify vessel depth, size, thrombus, respiratory variation, and carotid artery overlap before puncture, thereby supporting safer access planning. It also allows operators to choose a different route before tissue trauma occurs.

The study supports routine use of ultrasound guidance wherever trained personnel and equipment are available.

Nevertheless, landmark knowledge remains important because emergencies, equipment malfunction, and resource-limited settings still occur. A balanced training strategy should therefore include vascular anatomy, ultrasound image acquisition, needle visualisation, aseptic technique, and management of failed access. The findings from this study add institutional data from a tertiary care centre in Telangana and reinforce the role of ultrasound guidance as a practical method to improve central venous access safety and efficacy.

Limitations: This was a single-centre study with a modest sample size of 60 patients. Operator experience, catheter insertion site, and patient anatomy were not stratified in detail. Long-term outcomes such as catheter-related bloodstream infection and thrombosis were not assessed. The study focused mainly on immediate procedural efficacy and mechanical complications.

CONCLUSION

Ultrasound-guided central venous catheterisation was more effective and safer than the landmark technique in this prospective comparative study. It provided significantly higher first-attempt success, fewer needle puncture attempts, and shorter catheterisation time. Overall success was higher with ultrasound guidance, while complications such as arterial puncture, haematoma, pneumothorax, and catheter malposition were less frequent. These findings support the routine use of ultrasound guidance for central venous access in tertiary care practice. Landmark technique retains value where ultrasound facilities are unavailable, but ultrasound-guided access should be preferred when equipment and trained operators are accessible. Wider training can improve procedural safety and patient outcomes.

Financial support and sponsorship

Nil.

Conflicts of interest

There are no conflicts of interest.

REFERENCES

1. Practice Guidelines for Central Venous Access 2020: An Updated Report by the American Society of Anesthesiologists Task Force on Central Venous Access. *Anesthesiology*. 2020;132(1):8-43. doi:10.1097/ALN.0000000000002864.
2. Troianos CA, Hartman GS, Glas KE, Skubas NJ, Eberhardt RT, Walker JD, et al. Guidelines for performing ultrasound guided vascular cannulation: recommendations of the American Society of Echocardiography and the Society of Cardiovascular Anesthesiologists. *J Am Soc Echocardiogr*. 2011;24(12):1291-1318. doi:10.1016/j.echo.2011.09.021.
3. Saugel B, Scheeren TWL, Teboul JL. Ultrasound-guided central venous catheter placement: a structured review and recommendations for clinical practice. *Crit Care*. 2017;21(1):225. doi:10.1186/s13054-017-1814-y.
4. Brass P, Hellmich M, Kolodziej L, Schick G, Smith AF. Ultrasound guidance versus anatomical landmarks for internal jugular vein catheterization. *Cochrane Database Syst Rev*. 2015;(1):CD006962. doi:10.1002/14651858.CD006962.pub2.
5. Hind D, Calvert N, McWilliams R, Davidson A, Paisley S, Beverley

- C, et al. Ultrasonic locating devices for central venous cannulation: meta-analysis. *BMJ*. 2003;327(7411):361. doi:10.1136/bmj.327.7411.361.
6. McGee DC, Gould MK. Preventing complications of central venous catheterization. *N Engl J Med*. 2003;348(12):1123-1133. doi:10.1056/NEJMra011883.
 7. Parienti JJ, Mongardon N, Mégarbane B, Mira JP, Kalfon P, Gros A, et al.; 3SITES Study Group. Intravascular complications of central venous catheterization by insertion site. *N Engl J Med*. 2015;373(13):1220-1229. doi:10.1056/NEJMoa1500964.
 8. Miller AH, Roth BA, Mills TJ, Woody JR, Longmoor CE, Foster B. Ultrasound guidance versus the landmark technique for the placement of central venous catheters in the emergency department. *Acad Emerg Med*. 2002;9(8):800-805. doi:10.1111/j.1553-2712.2002.tb02168.x.
 9. Milling TJ Jr, Rose J, Briggs WM, Birkhahn R, Gaeta TJ, Bove JJ, et al. Randomized, controlled clinical trial of point-of-care limited ultrasonography assistance of central venous cannulation: the Third Sonography Outcomes Assessment Program (SOAP-3) Trial. *Crit Care Med*. 2005;33(8):1764-1769. doi:10.1097/01.CCM.0000171533.92856.E5.
 10. Karakitsos D, Labropoulos N, De Groot E, Patrianakos AP, Kouraklis G, Poularas J, et al. Real-time ultrasound-guided catheterisation of the internal jugular vein: a prospective comparison with the landmark technique in critical care patients. *Crit Care*. 2006;10(6):R162. doi:10.1186/cc5101.
 11. Turker G, Kaya FN, Gurbet A, Aksu H, Erdogan C, Atlas A. Internal jugular vein cannulation: an ultrasound-guided technique versus a landmark-guided technique. *Clinics (Sao Paulo)*. 2009;64(10):989-992. doi:10.1590/S1807-59322009001000009.
 12. Fathi M, Izanloo A, Jahanbakhsh S, Taghavi Gilani M, Majidzadeh A, Sabri Benhangi A, et al. Central venous cannulation of the internal jugular vein using ultrasound-guided and anatomical landmark techniques. *Anesth Pain Med*. 2016;6(3):e35803. doi:10.5812/aapm.35803.
 13. Kunhahamed MO, Abraham SV, Palatty BU, Krishnan SV, Rajeev PC, Gopinathan V. A comparison of internal jugular vein cannulation by ultrasound-guided and anatomical landmark technique in resource-limited emergency department setting. *J Med Ultrasound*. 2019;27(4):187-191. doi:10.4103/JMU.JMU_2_19.
 14. Sazdov D, Jovanovski-Srceva M, Todorova ZN. Comparative analysis of ultrasound guided central venous catheterization compared to blind catheterization. *Pril (Makedon Akad Nauk Umet Odd Med Nauki)*. 2017;38(2):107-114. doi:10.1515/prilozi-2017-0028.